

Annular intubation with pigtail probe for canalicular lacerations

Rajat D Maheshwari, Maanvi Maheshwari¹

Purpose: Pigtail probe as a procedure of choice for canalicular laceration. **Methods:** Retrospective, consecutive interventional case series of patients with eyelid laceration involving the canaliculus undergoing repair. All patients were subjected to repair with pigtail probe as first choice and only if this was not possible, they were repaired by other method. Outcome was analyzed in terms of cosmetic, functional, and anatomic success. **Results:** A total of 35 patients (mean age, 10.88 years) underwent eyelid and canaliculus repair by a single surgeon (RM). In all, 32 (91.42%) canalicular lacerations were repaired by annular intubation using a pigtail probe, while the remaining 3 (8.58%) lacerations in which pigtail probe intubation was not possible, were repaired by an alternative method. Upper canaliculus was involved in 6 (17.14%) and lower canaliculus in 29 (82.86%) eyes. Mean follow-up was 8.2 months (range 3–13 months). Intubation tubes were removed after at least 3 months (range 12–20 weeks). None of the patients had complaints of epiphora. All the patients had good cosmesis, anatomic alignment and functional success as assessed by dye disappearance test in younger children and lacrimal irrigation in older children and adults. **Conclusion:** Bicanalicular annular repair with pigtail probe achieved excellent functional and cosmetic results. The loop minimizes the chances of extrusion of the tube, maintains natural anatomic alignment of the cut ends of the canaliculus and thus retains the integrity of the delicate canalicular system. Pigtail probe intubation can be considered as the first choice in canalicular lacerations.

Key words: Canaliculus, laceration, pigtail probe

Canalicular laceration are a common finding in injuries involving the lids and especially more so where it is close to the medial canthus and has been reported in all age groups. Repair of eyelid lacerations without attention to the canaliculus will invariably always result in occlusion of the canaliculus and thus mandates a primary repair.^[1,2] One utmost important step in the management of a torn canaliculus is placement of a stent to prevent stricture of the canalicular lumen during the healing process.^[1-4] Second major success parameter is proper alignment of the torn canaliculus such that integrity of the canalicular system is maintained. Management of canalicular laceration varies widely and different surgical techniques have been described by various authors over the years. The use of pigtail probe has not been a very popular method because of poor surgical results, risk of trauma to the uninvolved canaliculus, and the technique being more demanding.^[2,5-8] Recent studies have however, shown good surgical results with the round tip eyed pigtail probe.^[3,8,9] Silicone has been a preferred material for stenting and good success rate using Crawford intubation system has been reported by earlier authors.^[2,5,10-12] In this study the author reports success with annular intubation with pigtail probe for consecutive cases of canalicular lacerations performed as procedure of choice.

Methods

This is a retrospective review of consecutive cases of canalicular lacerations repaired by single lacrimal surgeon from September 2015 to September 2019. In total 35 patients underwent canalicular repair of which annular intubation using round tip eyed pigtail probe [Fig. 1] was successful in 32 eyes. In 3 eyes annular intubation was not possible and was repaired by other method. The age ranged from 11 months to 46 years (mean 10.88 years). Bi-canalicular annular intubation was done with a 20G silicone tube threaded by 5-0 prolene suture [Fig. 2]. The annular intubation tubes were removed minimum 3 months after surgery. Anatomical success was defined by irrigation in older children and adults, functional success was determined by dye disappearance test in small children.

Surgical technique

After appropriate anesthesia and localization of the canalicular laceration a round tip, eyed pigtail probe was passed through the normal punctum and rotated to emerge from the medial cut end of the torn canaliculus [Fig. 3a]. Eye of the pigtail probe is threaded by 5-0 prolene suture which is passed through 20G silicone tube. Pigtail probe is then rotated back to emerge from the normal punctum [Fig. 3b]. Next the prolene

Access this article online

Website:

www.ijo.in

DOI:

10.4103/ijo.IJO_8_20

Quick Response Code:



EyeLid, Orbit & Ocular Oncology, Netraseva, Jalna, Maharashtra, ¹Department of Chemical Engineering, Shiv Nadar University, Dadri, Greater Noida, UP, India

Correspondence to: Dr. Rajat D Maheshwari, Netraseva, Eastern Greens, Mantha Square, Jalna - 431 203, Maharashtra, India. E-mail: rajat.oculoplasty@gmail.com

Received: 02-Jan-2020

Revision: 10-Feb-2020

Accepted: 29-Mar-2020

Published: 23-Sep-2020

This is an open access journal, and articles are distributed under the terms of the Creative Commons Attribution-NonCommercial-ShareAlike 4.0 License, which allows others to remix, tweak, and build upon the work non-commercially, as long as appropriate credit is given and the new creations are licensed under the identical terms.

For reprints contact: WKHLRPMedknow_reprints@wolterskluwer.com

Cite this article as: Maheshwari RD, Maheshwari M. Annular intubation with pigtail probe for canalicular lacerations. Indian J Ophthalmol 2020;68:2166-9.

suture is guided through the distal cut end of the canaliculus to emerge from the lacerated punctum [Fig. 3c]. The silicone tube thus forms a loop passing through the entire length of the canalicular system [Fig. 3d]. The eyelid wound is now repaired and peri-canalicular suturing done to ensure approximation of the cut canalicular mucosal tissue with 7-0 Vicryl suture. The 5-0 prolene suture is tied such that the two ends of the silicone tube get approximated, the silicone tube is then rotated to move the cut ends of the tube in the canaliculus.

Results

Total 35 consecutive canalicular lacerations were repaired over 4 years duration. Silicone tube intubation with pigtail

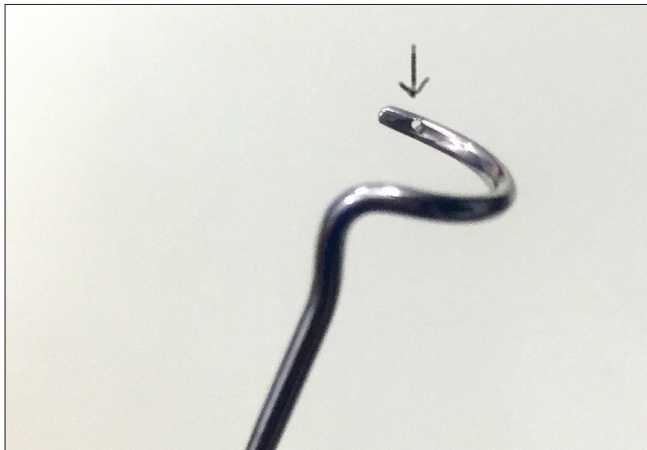


Figure 1: Pig tail probe with round tip and eye (black arrow)

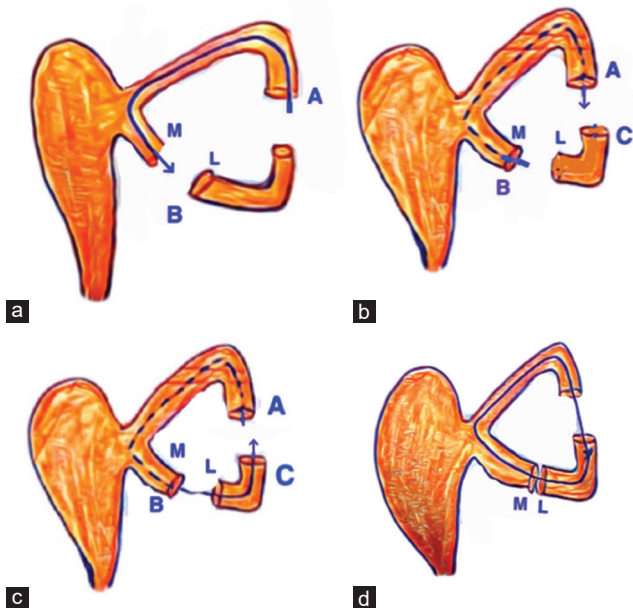


Figure 3: (a) Probe enters from the normal punctum (A) and rotated to emerge from the medial end of the lacerated canaliculus (M). (b) A 5-0 prolene suture threaded on the silicone tube is passed through the eye of the probe and the probe is rotated back from the medial cut end of the canaliculus (M) to emerge from the upper punctum (A). (c) The 5-0 prolene suture is passed from the lateral end of the lacerated canaliculus (L) to emerge from the lower punctum (C). (d) A loop is thus formed of silicone tube passing the canalicular passage

probe was possible successfully in 32 eyes. In 3 eyes (9.37%) the procedure had to be abandoned as there was resistance to passage of pigtail probe. The lower canaliculus was involved in 29 (82.86%) patients and upper canaliculus in 6 (17.14%) patients. Common etiologies were injury by blouse hook and trauma by sharp object (metal hook). In all patients surgery was performed within 48 h. Surgery was performed under general anaesthesia in 28 patients and local anaesthesia in 7 patients. The silicone tubes were left in place for an average 5.2 months postsurgery. Follow-up ranged from 12 to 21 weeks after tube removal (mean 4.6 months). None of the patients had premature extrusion of the intubation tube. Saline irrigation of the lacrimal passage could be performed in 7 patients and showed patent nasolacrimal passage. Irrigation could not be performed in rest all pediatric patients in whom success was assessed by dye disappearance test. There were no complications and all patients had good functional and cosmetic outcome [Figs. 4-6a and b].

Discussion

Laceration of the canaliculus is commonly an associated finding in injuries involving the eyelids. Any injury close to the lid margin and medial to the punctum, a canalicular injury should be suspected. Canalicular lacerations usually result either from blunt indirect trauma or by avulsing or shearing forces.^[2,12,13] Repair of the torn canaliculus is aimed with restoring the patency of the system such that it retains its functional property. This requires placement of a stent to prevent stricture of the cut ends of the canaliculus.

Methods available include monocanalicular stenting^[1,2,14-18], bi-canalicular stenting with nasal fixation^[1,2,19,20], and bi-canalicular annular stenting using a pigtail probe.^[1-3,8,9,16]

The author reports repair by bi-canalicular annular intubation by pigtail probe as the procedure of choice for all




Figure 2: Figure showing passage of 5-0 prolene suture threaded on 20G silicone tube through the eye of the pigtail probe

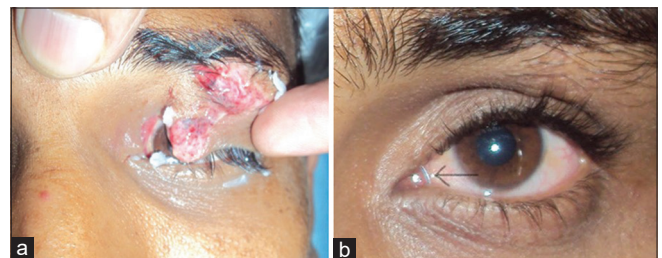


Figure 4: (a) Left upper eyelid lacerations, (b) post repair with silicone tube

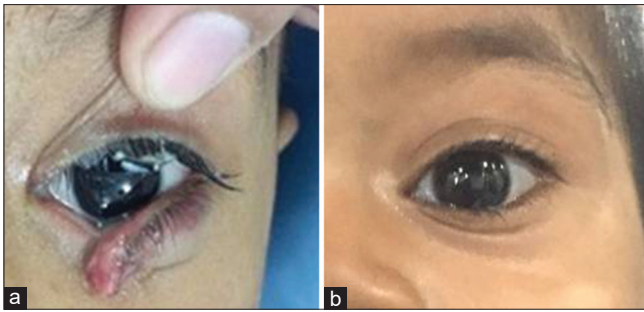


Figure 5: Left lower eyelid and Canalicular laceration (a), Post repair with silicone loop seen at the medial canthus (black arrow b)

lacerations and only when this was not possible were repaired by other technique. The main advantage of annular intubation is it keeps the cut ends of the canaliculus approximated in its normal anatomical alignment because both the upper and lower canaliculus are held in a continuous loop^[2] and also it minimizes the chances of extrusion. As an early example of bicanalicular-annular stent, Stallard^[21] cited Greaves technique of bicanalicular annular stent placement with nylon suture. Bicanalicular stent placement using a pigtail probe was described by Worst in 1962.^[22] The Worst pigtail probe had a sharp crochet hook at the tip and was not popular because of the risk of damaging the canalicular system and creating a false passage. An important modification to the Worst probe later was replacement of the sharp barbed tip with round eyed probe through which a stent or suture guide could be threaded.^[9]

The pigtail probe however, has not been very popular with lacrimal surgeons over the years because the passage of probe through the canalicular system is technically difficult and requires expertise, also there is a potential risk of damaging the common canaliculus or the normal canaliculus.^[2,5-7,15,23-25] One genuine limitation of the technique is the canalicular system where there is no common canaliculus, reported in 10% of canaliculus.^[26]

In a series of 222 canalicular laceration repairs by Kennedy *et al.*^[6] a higher incidence of epiphora was noted in cases where pigtail probes was used. Saunders *et al.*^[24] also reported a 10% incidence of trauma to the normal canaliculus using pigtail probe repair. None report specifically as to the Worst probe (which has a sharp tip) or the round tip probe was used. More recent studies where round tip pigtail probe were used have reported good success rate with bicanalicular annular intubation. Jordan *et al.*^[9] described the use of a more atraumatic round-tipped, eyed pigtail probe in 33 of their patients with a 97% success rate. McLeish *et al.*^[8] used the round tipped pigtail probe and they suggested further reducing the risk of damage with simultaneous use of the Crawford intubation stent as a guide to direct the passage of the probe through the normal canaliculus. Forbes *et al.*^[3] described a hybrid technique using a eyed round tipped pigtail probe and monocalicular stent and reported an excellent success rate.

It is advised to maneuver the pigtail probe very gently without any force to prevent any false passage. One should be aware that 10% of the canalicular systems do not have a common canaliculus,^[26] hence should not forcibly overcome an obstruction, rather abandon the procedure in favor of alternative method of repair.

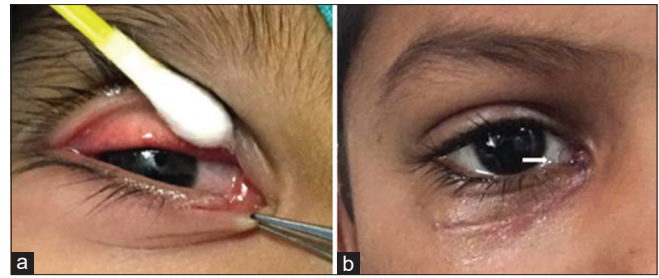


Figure 6: Right lower eyelid with canalicular laceration (a), Post repair with silicone intubation tube seen at the medial canthus (b)

Various different materials have been historically used as canalicular stents. Silicone has gained popularity as the ideal stent as it is inert, soft and pliable, thus avoiding trauma to the healing tissues also its stability and inert nature allows it to remain *in situ* for a longer period.^[2] Crawford or Ritleng stents have been commonly used for canalicular intubation. Both these stents are expensive and availability a major issue in developing nations. Jordan, Nerad and Tse^[9] have described use of silicone stent passed over suture for bicanalicular annular intubation with good success rate. We used the same technique described by Jordan *et al.* for bi-canalicular annular intubation. The main advantage with our technique is an indigenously prepared intubation system which is cost effective and can be readily prepared from locally available lacrimal intubation tube. This is especially useful in large part of the developing world where standard healthcare is not available to large segment of the population because of economic constraints. The main limitation of this technique as discussed above is in cases where common canaliculus is absent and as such the maneuvering of the probe should be very gentle and should one encounter resistance this should be abandoned in favor of some alternative technique.

The timing of stent removal has been a matter of personal choice and varied in different earlier studies from 3 to 12 months. Conlon *et al.*^[27] studied the histology of canalicular lacerations following intubation on animal model and showed that the optimum time for removal of tube was 12 weeks in an animal model. Kersten and Kulvin^[28] left silicone stents in place for three months in their patients with 100% patency. Jordan *et al.*^[9] left the silicone stent in place for 12 months with good results. There is evidence to support that stent should be left in place for at least 3 months for mucosal anastomosis to take place thus minimizing the risk of canaliculus stricture.^[27] Naik *et al.*^[17] have emphasized the importance of stent retainment by stating that failure to achieve canalicular patency correlated with premature stent loss. In our study annular intubation tube were removed a minimum after 3 months. There were no cases of tube extrusion. There were no complications, none of the patient complained of epiphora and all had good cosmetic and functional outcome.

Conclusion

To summarize, canalicular laceration should be suspected in all cases involving injury to the eyelids. Bicanalicular annular repair with round tipped, eyed pigtail gives excellent success rate and can be the first choice for canalicular repair. Another advantage of the annular intubation as described earlier is maintaining the canaliculus in its normal anatomical alignment

because of the continuous silicone loop and has good stent retainment which is an important criteria for anatomical and functional success of the procedure. As the length of the silicone tube is kept in compliance with the canalicular anatomy it does not cause any injury to the ocular tissues other than the added advantage of not being inadvertently pre-removed by patients accidentally or otherwise.

Acknowledgement

Maanvi Maheshwari for images.

Declaration of patient consent

The authors certify that they have obtained all appropriate patient consent forms. The patients/Guardians have consented to give their image and clinical information to be reported in the journal. The patients understand that their names and initials will not be published and due efforts will be made to conceal their identity, but anonymity cannot be guaranteed.

Financial support and sponsorship

Nil.

Conflicts of interest

There are no conflicts of interest.

References

- Nerad JA. Techniques in Ophthalmic Plastic Surgery: A Personal Tutorial. 1st ed.. Saunders Elsevier; 2010.p. 361-8.
- Reifler DM. Management of canalicular lacerations. *Surv Ophthalmol* 1991;36:113-3.
- Forbes BJ, Katowitz WR, Binenbaum G. Pediatric canalicul tear repairs-revisiting the pigtail probe. *JAAPOS* 2008;12:518-20.
- Sendul SY, Cagatay HH, Dirim B, Demir M, Cinar S, Ucgul C, *et al.* Reconstructions of the traumatic canalicular lacerations: A 5 year experience. *Open Access J Sci Technol* 2015;3:1-6.
- Anderson RL, Edwards JJ. Indications, complications and results with silicone stents. *Ophthalmology* 1979;86:1474-87.
- Kennedy RH, May J, Dailey J, Flanagan JC. Canalicular laceration. *Ophth Plast Reconstr Surg* 1990;6:46-53.
- Canavan YM, Archer DB. Long term reviews of injuries to the lacrimal apparatus. *Trans Ophthalmol Soc UK* 1979;99:201-4.
- McLeish WM, Bowman B, Anderson RL. The pigtail probe protected by silicone intubation: A combined approach to canalicular reconstruction. *Ophthalmic Surg* 1992;23:281-3.
- Jordan D, Nerad JA, Tse DT. The pigtail probe, revisited. *Ophthalmology* 1990;97:512-9.
- Lauring L. Silicone intubation of the lacrimal system: Pitfalls, problems and complications. *Ann Ophthalmol* 1976;8:489-98.
- Kraft SP, Crawford J. Silicone tube intubation in disorders of the lacrimal system in children. *Am J Ophthalmol* 1982;94:290-9.
- Tint NL, Alexander P, Cook AE, Leatherbrow B. Eyelid avulsion repair with bi-canalicular silicone stenting without medial canthal tendon reconstruction. *Br J Ophthalmol* 2011;95:1389-92.
- Zide BM, McCarthy JG. The medial canthus revisited: An anatomical basis for canthoplexy. *Ann Plast Surg* 1983;11:1-9.
- Anderson RL. Medial canthal tendon branches out. *Arch Ophthalmol* 1977;95:2051-2.
- Hing SJ. A retrospective review of canaliculus injuries in Auckland. *Trans Ophthalmol Soc N Z* 1984; 36:72-3.
- Romano PE. Single silicone intubation for repair of single canaliculus laceration. *Ann Ophthalmol* 1986;18:112-13.
- Naik MN, Kelapure A, Rath S, Honavar SG. Management of canalicular lacerations: Epidemiological aspects and experience with mini-monoka monocanalicular stent. *Am J Ophthalmol* 145;2:375-80.
- Chatterjee S, Rath S, Roy A, Shrestha E. 20G silicone rod as monocanalicular stent in repair of canalicular lacerations: Experience from a tertiary eye care centre. *Indian J Ophthalmol* 2013;61:585-6.
- Craford JS. Intubation of the obstructions in the lacrimal system. *Can J Ophthalmol* 1977;12:4:289-92.
- Guibor P. Canalicular intubation set. *Trans Sect Ophthalmol Am cad Ophthalmol Otolaryngol* 1975;79:2:419-20.
- Stallard HB. *Eye Surgery*. 4 ed. Bristol, UK: Jhon Wright and Sons Ltd; 1965. p. 277-340.
- Worst JGF. Method for reconstructing torn lacrimal canaliculus. *Am J Ophthalmol* 1962;53:520-2.
- Hinj SJ. A retrospective study of lacrimal injuries in Auckland. *Trans Ophthalmol Soc N Z* 1984;36:72-3.
- Saunders DH, Shannon GM, Flanagan JC. The effectiveness of pigtail probe method of repairing canalicular lacerations. *Ophthalmic Surg* 1978;9:33-40.
- Pecora JL. Pediatric nasolacrimal pigtail probes. *Ophthalmic Surg* 1980;11:4:249.
- Jones LT, Rech MJ, Wirtshafter JD. *Ophthalmic Anatomy: A Manual with Some Clinical Applications*. Rochester (MN): American Academy of Ophthalmology and Otolaryngology; 1970. p. 67-8.
- Conlon MR, Smith KD, Cadera W, Shum D, Allen LH. An animal model studying reconstruction techniques and histopathological changes in repair of canalicular lacerations. *Can J Ophthalmol* 1994;29:3-8.
- Kersten RC, Kulwin DR. "One stitch" canalicular repair. *Ophthalmology* 1996;103:785-90.